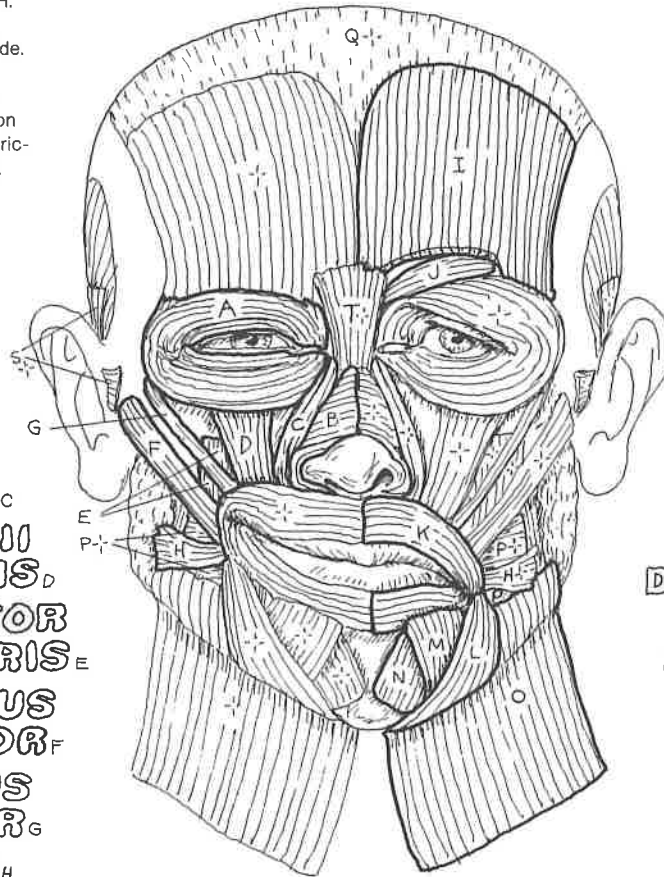


# V. MUSCULAR SYSTEM/HEAD

## MUSCLES OF FACIAL EXPRESSION

CN: Use your lightest colors for O and Q.  
 Use warm and cheerful colors for the muscles producing a smile (A-H). Color the muscles reflecting sadness (I-O) with greens, blues, and grays. (1) Begin with the smiling side, and color only the muscles identified by titles A-H. Also color those muscles in the profile view below. (2) Repeat the process with the sad side. Note that a portion of frontalis (I) has been cut away to reveal procerus (J). (3) Color the titles at the bottom and the related muscles on the lower view. Include the portions of the auricular muscles that disappear beneath the ear.

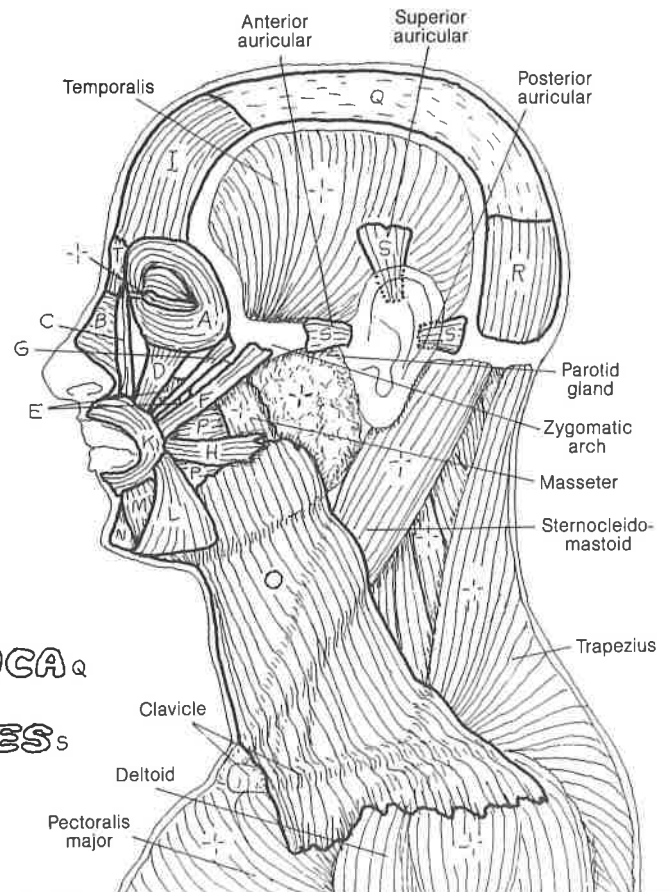


ORBICULARIS OCULI<sub>A</sub>  
 NASALIS<sub>B</sub>  
 LEVATOR LABII SUPERIORIS ALAEQUE NASI<sub>C</sub>  
 LEVATOR LABII SUPERIORIS<sub>D</sub>  
 LEVATOR ANGULI ORIS<sub>E</sub>  
 ZYGOMATICUS MAJOR<sub>F</sub>  
 ZYGOMATICUS MINOR<sub>G</sub>  
 RISORIUS<sub>H</sub>

FRONTALIS<sub>I</sub>  
 CORRUGATOR SUPERCILII<sub>J</sub>  
 ORBICULARIS ORIS<sub>K</sub>  
 DEPRESSOR ANGULI ORIS<sub>L</sub>  
 DEPRESSOR LABII INFERIORIS<sub>M</sub>  
 MENTALIS<sub>N</sub>  
 PLATYSMA<sub>O</sub>

The muscles of facial expression are generally thin, flat bands arising from a facial bone or cartilage and inserting into the dermis of the skin or the fibrous tissue enveloping the sphincter muscles of the orbit or mouth. These muscles are generally arranged into the following regional groups: (1) epicranial group (*occipitofrontalis* moving the scalp); (2) the orbital group (*orbicularis oculi*, *corrugator supercilii*); (3) the nasal group (*nasalis*, *procerus*); (4) the oral group (*orbicularis oris*, *zygomaticus major* and *minor*, the *levators* and the *depressors* of the lips and angles of the mouth, *risorius*, *buccinator*, and part of *platysma*), and (5) the group moving the ears (*auricular muscles*). The general function of each of these muscles is to move the skin wherever they insert. As you color each muscle, try contracting it on your self while looking into a mirror, and see what develops.

Orbicularis oculi and oris are sphincter muscles, tending to close the skin over the eyelids and tighten the lips, respectively. Contractions of the cheek muscle buccinator makes possible rapid changes in volume of the oral cavity, as in playing a trumpet or squirting water. The nasalis muscle has both compressor and dilator parts which influence the size of the anterior nasal openings.



GALEA APONEUROTICA<sub>Q</sub>  
 OCCIPITALIS<sub>R</sub>  
 AURICULAR MUSCLES<sub>S</sub>  
 PROCERUS<sub>T</sub>  
 BUCCINATOR<sub>P</sub>

Anterior auricular  
 Superior auricular  
 Posterior auricular  
 Temporalis  
 Parotid gland  
 Zygomatic arch  
 Masseter  
 Sternocleidomastoid  
 Trapezius  
 Clavicle  
 Deltoid  
 Pectoralis major